

Laparoscopic Versus Open Retrorectus Mesh Repair of Incisional and Ventral Hernia: A Randomised Clinical Study

MUKUND PRABHAKAR KULKARNI



ABSTRACT

Introduction: Hernias are defects or holes in the abdominal wall with protrusion of abdominal contents and are common problems in daily surgical practice. The defects can develop following previous surgical procedure or can be primary in the absence of any past surgery. The operative repair of these hernias can be done by either open procedure or laparoscopic surgery.

Aim: To compare the laparoscopic hernia repair with open surgical repair in terms of operative time, hospital stay, pain, complications, cost and recurrence.

Materials and Methods: This randomised clinical study was conducted from April 2015 to December 2019. Patients undergoing elective surgery for primary ventral hernias and incisional hernias were included. There were 50 patients who underwent open mesh repair and 50 patients who had laparoscopic repair. The

data was analysed using Mann-Whitney U test for continuous variables and Chi-square test for categorical variables.

Results: The patients were comparable for age and sex distribution and also the type of hernia, primary ventral or incisional, size of defect and body mass index in both the groups. The patients undergoing laparoscopic mesh repair had significantly less operative time (90 vs 110 minutes, $p=0.036$), reduced postoperative pain ($p=0.001$) and decreased hospital stay (3.47 vs 6.43 days $p=0.0005$). The cost of the laparoscopic surgery was significantly high (p -value 0.0001) basically owing to the cost of mesh and disposable tacker. The recurrence at mean follow-up of 13 months was similar in both the groups.

Conclusion: Laparoscopic hernia repair is superior to open repair in select group of patients with small and medium size defects without loss of abdominal domain if cost is not a consideration.

Keywords: Hernia repair, Hernia recurrence, Tacker, Transfascial fixation

INTRODUCTION

The surgical technique for hernia repair has evolved over time from suture repair, to mesh repair. The position of mesh can be underlay also called retrorectus or onlay. The material used for mesh also varies and include polyester, polypropylene and Polytetrafluoroethylene (PTFE) [1]. The size of pores in the mesh varies microporous or lightweight macroporous. The fear of adhesions and mesh erosion has given rise to use of dual mesh for laparoscopic repair [2].

The advent of laparoscopic surgery is one more advancement in this effort. The laparoscopic surgery is excellently suited for primary ventral hernias and incisional hernia without loss of abdominal domain [3]. The laparoscopic technique described as Intraperitoneal Onlay Mesh (IPOM) repair consisted of placing the mesh as a bridge with wide overlap all around, has also undergone changes like primary suture closure of the defect with intracorporeal suturing (IPOM Plus) [3] and use of two to four transfascial sutures along with non-absorbable or absorbable tacks [4], all aimed at reducing recurrence. The laparoscopic technique is still not popular in this part of our state because some are not convinced about its advantages and some find it more costly because of high cost of laparoscopic set-up and cost of consumables. To carry out randomised study in a heterogenous disease such as hernia is a challenging task especially in resource deficient setups like ours. The previous studies [5-7] which compared the laparoscopic repair with open retrorectus repair earlier have compared the bridging technique of laparoscopic repair (IPOM), whereas the current study aims to compare with IPOM Plus or primary suture closure in addition to mesh technique.

The study was conducted to compare the laparoscopic hernia repair using this improved technique with open mesh repair for incisional and primary ventral hernias in terms of operative time, pain, hospital stay, complications, recurrence and cost.

MATERIALS AND METHODS

This prospective, randomised clinical study was done at Karnataka Institute of Medical Sciences Hubli in Karnataka, India between April 2015 and December 2019. The Institutional Ethical Committee approval was taken vide letter no. KIMS/EC/80/2015-16. Written informed consent was taken from each of participating patient.

Inclusion criteria: Patients above 18 years of age admitted for elective repair of incisional and primary ventral hernias were included.

Exclusion criteria: Patients unfit for general anaesthesia, patients with obstruction or strangulation, ascites, and hernias with significant domain loss which preclude anatomical closure of defect and need abdominal wall reconstruction were excluded. Patients who had an associated enteric fistula, ileostomy or colostomy were also excluded.

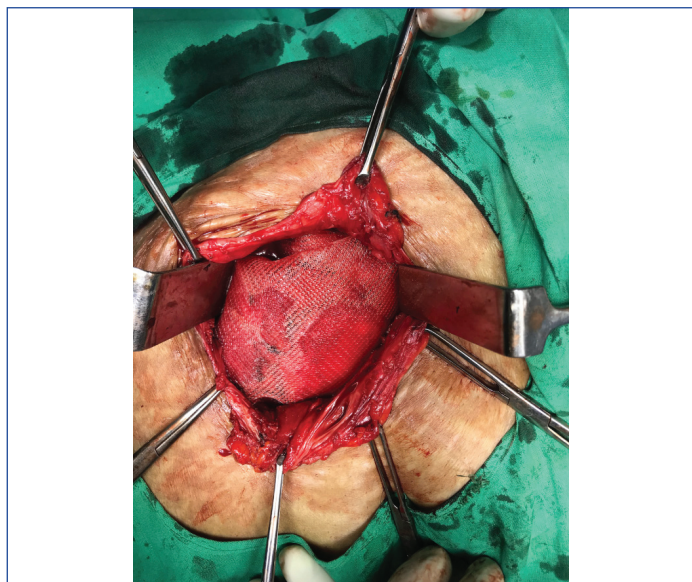Sample size calculation and randomisation: With an α (alpha) error of 0.05 and power of 0.80 an estimated 90 patients were needed to detect a 2 point change in the pain scores on visual analogue scale. Assuming 10% dropout 100 patients (50 in each group) were included. Randomisation was done using sealed envelopes. The envelope was picked up at random once the patient agreed to participate in the study. Both laparoscopic and open procedures were done by the same surgeon. The procedures were done using standard established techniques as described below.

Study Procedure

Preoperative preparation: The patients were given chest physiotherapy with regular steam inhalation and incentive spirometer exercises. The local skin ailments and fungal infections treated with topical and if necessary oral antifungals in consultation with skin specialists. Patients, received single dose of antibiotic with ceftriaxone.

Open Technique

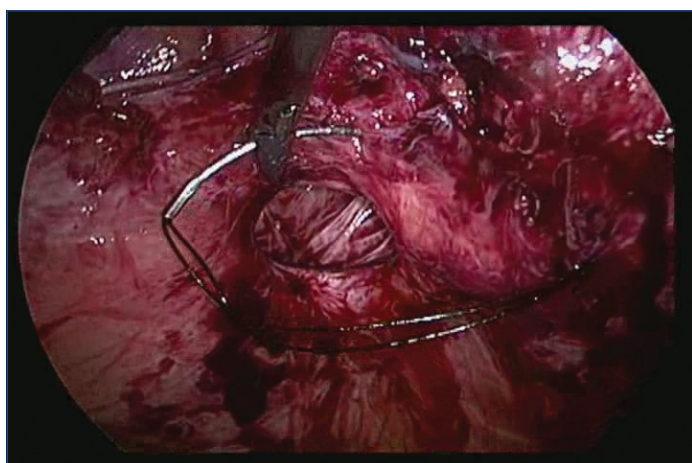
It followed the technique first described by Rives J et al., and Stoppa RE. The procedure consisted of opening the sac and reducing the contents [8,9]. The posterior rectus sheath, or in case of below arcuate line the peritoneum was separated from rectus muscle and approximated in midline with 2-0 polydioxanone sutures. An appropriate size polypropylene mesh to give at least 5 cm overlap all around placed over the posterior sheath and secured with few sutures all over [Table/Fig-1]. The anterior rectus sheath closed over the mesh. The skin was closed without any drains as no or very minimal subcutaneous plane was dissected. Whenever intestinal injury or enterotomy was recognised it was promptly repaired in two layers and saline wash given.



[Table/Fig-1]: Polypropylene mesh secured with suture at the place.

Laparoscopic Repair

This technique was first described by LeBlanc KA and Both WV [10]. The pneumoperitoneum was created using Veress needle at Palmer's point. A 10 mm port placed for camera and two 5 mm ports placed for instruments achieving triangulation keeping sufficient space for mesh fixation. All the omental and bowel adhesions were taken down with sharp dissection. The defect was closed by intracorporeal suturing with no. 1 loop nylon [Table/Fig-2]. The dual mesh was secured with four corner trans fascial fixation sutures and multiple absorbable tacks [Table/Fig-3]. A tampon was placed over the site of defect and pressure dressing applied to prevent seroma formation. When there was intraoperative identification of inadvertent intestinal injury, abdomen was opened with a small incision over the skin of the hernia and bowel repaired in two-layer sutures. Saline wash was given and bowel put back into abdomen and skin closed. The laparoscopic procedure was continued.



[Table/Fig-2]: Intracorporeal suture with nylon no. 1 loop.



[Table/Fig-3]: Dual mesh secured with transfacial fixation sutures.

Postoperative care: The patients received intravenous fluids, antibiotics and analgesics. Intravenous paracetamol one gram every eight hours was given along with injection tramadol 100 mg intravenous 12 hourly till patient was started on oral analgesics. Additional analgesia was given when needed with twenty micrograms of injection fentanyl. At the time of discharge, similar oral analgesics, paracetamol and tramadol were prescribed. The patients were encouraged early ambulation and started orally as soon as tolerated. The pain was assessed using Visual Analogue Score (VAS) 1 to 10. The patients were followed-up regularly at one month and subsequently at three-month intervals for the first year and then at 6 monthly intervals till the time the results of this study were analysed. The cost was calculated by accounts department by taking into consideration the hospitalisation, operation theater charges, equipment charges, and cost of consumables including mesh and tacker and the cost of medicines.

STATISTICAL ANALYSIS

All patient data were analysed with intention to treat basis. The data were entered into Microsoft Excel work sheet. The continuous variables were compared with Mann-Whitney U test and categorical variables with Chi-square test. A p-value of ≤ 0.05 was considered significant.

RESULTS

There were 50 patients each in open mesh repair and laparoscopic repair group. The patients in both groups were matched for age, sex, body mass index. There was no significant difference in hernia characters such as size of defect and location of defect [Table/Fig-4].

Parameters studied	Open surgery group (n=50)	Laparoscopic surgery group (n=50)	p-value
Age (Years) Mean (SD)	43 (12.24)	45.4 (14.56)	0.06*
Sex			
Male	27	31	0.65†
Female	23	19	
Body mass index, Mean (SD)	25.43 (6.8)	26.28 (5.2)	0.48*
Type of hernia			
Primary hernia	20	26	0.22†
Incisional	30	24	
Size of defect (cm ²) Mean (SD)	18.34 (14.20)	17.97 (11.13)	0.88*
Location of defect			
Upper abdominal	6	9	0.66†
Peri umbilical	12	15	
Lower abdominal	28	23	
Lateral	4	3	

[Table/Fig-4]: Demographic comparison between open retrorectus incisional and ventral hernia repair. SD: Standard deviation; *Mann-whitney U test; †chi-square test

The operative time was significantly less for the laparoscopic group (110 min for open versus 90 min for laparoscopic, $p=0.036$). The pain scores were significantly lower in the laparoscopic group on day 1, 2 and 3 [Table/Fig-5]. However, there was no difference in chronic pain at three and six months follow-up. Operative site complications mainly wound infection and seroma formation was comparable. The hospital stay was significantly more in the open mesh repair group. The cost of the laparoscopic repair was very high mainly due to the high cost of the dual mesh and absorbable tacker. At mean follow-up of one year, there was no significant difference in the recurrence rates.

Variables	Open surgery group n=50	Laparoscopic surgery group n=50	p-value
Operative time (Minutes) Mean \pm SD	110 (47.78)	90 (46.70)	0.036*
Enterotomy	3	2	0.21 [†]
Pain score (VAS)			
Day 1	6.05 (2.2)	4.10 (1.2)	0.0001*
Day 2	4.43 (1.9)	3.30 (1.4)	0.001*
Day 3	3.21 (1.80)	2.01(1.50)	0.0005*
No of patients with neuropathic pain at 3 months	3	6	0.265 [†]
No of patients with neuropathic pain at 6 months	2	2	0.966 [†]
Wound infection	2	1	0.72 [†]
Seroma/haematoma	2	4	
Mesh infection	0	0	
Hospital stay (Days), Mean (SD)	6.43 (4.98)	3.47 (2.72)	0.0005*
Cost (Rs) Mean (SD)	46000 (12000)	120000 (19000)	0.0001*
Follow-up			
Mean follow-up months, Mean (SD)	12.9 (4.6)	14.73 (5.2)	0.078*
Lost to follow-up	5	3	0.459 [†]
Recurrence	1	1	0.976 [†]

[Table/Fig-5]: Outcome comparison between open retrorectus and laparoscopic incisional and ventral hernia repair.

SD: Standard deviation; *Mann whitney U test; [†]chi-square test

DISCUSSION

According to our knowledge this is the first study comparing the open retrorectus mesh repair with laparoscopic mesh repair with suture closure of the defect. The laparoscopic group had significantly reduced operative time, improved postoperative pain scores and also reduced hospital stay. The intra and postoperative complications and recurrences were similar. The cost of laparoscopic surgery was very high.

At the time of commencement of this study, the literature search and review of meta-analysis showed the results of laparoscopic hernia repair and open mesh repair were comparable. The latest meta-analysis was published in February 2015 which comprised six randomised controlled trials [5] comparing the outcome of incisional hernias alone excluding primary ventral hernias citing different pathophysiology.

In various studies [6,7,11,12] the hernia defect was not closed in the laparoscopic groups. This allows the mesh to bulge out and be palpated subcutaneously. In the technique used in the present study, the closure of the defect by intracorporeal suturing, helps to give better strength and shape to the abdomen.

The laparoscopic operative time has been shown to be longer in one study [6] and shorter in another [12] although the recent meta-analysis [5] found no difference. Operative time is a function of defect size and the amount of adhesiolysis needed. Small defects and primary ventral hernias take less time in laparoscopy compared to larger defects and incisional hernias with severe adhesions. In the present study, the laparoscopic group needed lesser operative time compared to open repair.

Lesser pain following laparoscopic repair is used as a strong argument over open repair [5]. This is represented either as reduced analgesic requirements or reduced visual analogue scale scores. The reduced pain also contributes to reduced hospital stay and early discharge. In this study, the postoperative pain following laparoscopic repair was significantly less, similar to results shown by some studies [13,14], although some studies [11,12] found no difference. The chronic pain tends to be neuropathic and may be due to nerve entrapment in trans fascial fixation sutures and defect closure used in laparoscopic repair and extensive dissection and sheath closure in open surgery as suggested by Eker HH et al., [6].

The bowel injuries happen during first trocar insertion or during adhesiolysis [15,16]. Bowel injury can be managed either laparoscopically or by open conversion. Whether mesh will be placed or not depends on the injury, whether small bowel or colon is injured and amount of contamination [14,17]. In colonic injury or severe contamination, it is advised to postpone mesh placement, and place mesh at a delayed procedure [18]. In present study, when bowel injury was encountered, abdomen opened with a small incision for a complete assessment and repair. After repair was done and contamination, if any was washed, the laparoscopic repair was continued.

Wound related complications include wound infection, seroma, haematoma, wound dehiscence, mesh infection, sinus and enteric fistulas. By avoiding subcutaneous flap dissection, the problems of flap necrosis and wound infections were reduced. Drains also act as conduit for infection [19]. By avoiding drains, the wound infections were rare. Retained sacs contribute to seroma formation after laparoscopic repair. Many of them are asymptomatic and resolve over time and rarely require needle aspiration [20]. Routine use of pressure bandage over a tampon placed over the defect was used as suggested by some authors [7]. Eker HH et al., Rogermark P et al., and Itani KMF et al., showed significantly higher wound infection rates for open repairs compared to laparoscopic repairs [6,7,18]. Wound infection rates were comparable in two groups in Eker HH et al., study whereas Asencio F et al., noted no infections in either group [6,11]. The present study also showed comparable wound related complications.

Hospital stay is significantly shorter in laparoscopic repair group compared to open repair. The reduced tissue dissection, and reduced wound complications along with reduced pain help to achieve shorter hospital stay in laparoscopic group.

In the present study population where income is marginal and majority is uninsured, cost is a major factor in decision making more than any cosmesis. If the reduced operative time, reduced pain, hospital stay and wound complications can transform into reduced overall cost, it may make-up for the increased cost of laparoscopic equipment and consumables, namely dual mesh and tacker. As of now, as the cost of consumables is very high, laparoscopy works out to be more costly (Mean 46000 Rupees vs 120,000 Rupees).

Recurrence is another important factor in choice of hernia repair. Because late recurrence can occur as long as five to ten years [5] this study with short follow-up is not suited to answer this question. The use of four corner trans fascial fixation along with multiple tacks, help reduce recurrence in laparoscopic group.

Limitation(s)

This study suffers from low numbers and lack of adequate follow-up to detect recurrence. The follow-ups were by clinical examination only and not supported by cross-sectional imaging. The other parameters like improvement in effort tolerance and return to useful occupation are important outcomes which needed assessment.

CONCLUSION(S)

Laparoscopic hernia repair offers a superior solution for primary ventral and incisional hernias in patients with small and medium size

defects and without severe adhesions and loss of domain in terms of reduced operation times, less pain, early hospital discharge. At present the cost is significantly more.

REFERENCES

- [1] DeMaria EJ, Moss JM, Sugerman HJ. Laparoscopic intraperitoneal polytetrafluoroethylene (PTFE) prosthetic patch repair of ventral hernia. Prospective comparison to open prefascial polypropylene mesh repair. *Surg Endosc.* 2000;14 (4):326-29.
- [2] Ben-Haim M, Kuriansky J, Tal R, Zmora O, Mintz Y, Rosin D, et al. Pitfalls and complications with laparoscopic intraperitoneal expanded polytetrafluoroethylene patch repair of postoperative ventral hernia. *Surg Endosc.* 2002;16(5):785-88.
- [3] Suwa K, Okamoto T, Yanaga K. Is fascial defect closure with intraperitoneal onlay mesh superior to standard intraperitoneal onlay mesh for laparoscopic repair of large incisional hernia? *Asian J Endosc Surg.* 2018;11(4):378-84.
- [4] Brill JB, Turner PL. Long-term outcomes with transfascial sutures versus tacks in laparoscopic ventral hernia repair: A review. *The American Surgeon.* 2011;77(4):458-65.
- [5] Awaiz A, Rahman F, Hossain MB, Yunus RM, Khan S, Memon B, et al. Meta-analysis and systematic review of laparoscopic versus open mesh repair for elective incisional hernia. *Hernia.* 2015;19(3):449-63.
- [6] Eker HH, Hansson BM, Buunen M, Janssen IM, Pierik RE, Hop WC, et al. Laparoscopic vs. open incisional hernia repair: A randomised clinical trial. *JAMA Surg.* 2013;148(3):259-63.
- [7] Rogmark P, Petersson U, Bringman S, Eklund A, Ezra E, Sevoni D, et al. Montgomery A Short term outcomes for open and laparoscopic midline incisional hernia repair: A randomised multicenter controlled trial: The ProLOVE (prospective randomised trial on open versus laparoscopic operation of ventral eventrations) trial. *Ann Surg.* 2013;258(1):37-45.
- [8] Rives J, Pire JC, Flament JB. Treatment of large eventrations: New therapeutic indications apropos of 322 cases. *Chirurgie.* 1985;111(3):215-25.
- [9] Stoppa RE. The treatment of complicated groin and incisional hernias. *World J Surg.* 1989;13(5):545-54.
- [10] LeBlanc KA, Both WW. Laparoscopic repair of incisional abdominal hernia using expanded polytetrafluoroethylene: Preliminary findings. *Surg Laparosc Endosc.* 1993;3(1):39-41.
- [11] Asencio F, Aguiló J, Peiró S, Carbó J, Ferri R, Caro F, et al. Open randomised clinical trial of laparoscopic versus open incisional hernia repair. *Surg Endosc.* 2009;23(7):1441-48.
- [12] Olmi S, Scaini A, Cesana GC, Erba L, Croce E. Laparoscopic versus open incisional hernia repair: An open randomised controlled study. *Surg Endosc.* 2007;21(4):555-59.
- [13] Rosen M, Brody F, Ponsky J, Walsh RM, Rosenblatt S, Duprier F, et al. Recurrence after laparoscopic ventral hernia repair. *Surg Endosc.* 2003;17(1):123-28.
- [14] Henniford BT, Park A, Ramshaw BJ, Voeller G. Laparoscopic repair of ventral hernias: nine years' experience with 850 consecutive cases. *Ann Surg.* 2003;238(3):391-400.
- [15] Elieson MJ, LeBlanc KA. Enterotomy and mortality rates of laparoscopic incisional and ventral hernia repair: A review of the literature. *JLS.* 2007;11(4):408-14.
- [16] Toro A, Mannino M, Cappello G, Di Stefano A, Di Carlo I. Comparison of two entry methods for laparoscopic port entry: Technical point of view. *Diagn Ther Endosc.* 2012;2012:305428.
- [17] Bishoff JT, Allaf ME, Kirkels W, Moore RG, Kavoussi LR, Schroder F. Laparoscopic bowel injury: Incidence and clinical presentation. *J Urol.* 1999;161(3):887-90.
- [18] Itani KMF, Neumayer L, Reda D, Kim L, Anthony T. Repair of ventral incisional hernia: The design of a randomised trial to compare open and laparoscopic surgical techniques. *Am J Surg.* 2004;188(6A Suppl):22-29.
- [19] Pring CM, Tran V, O'Rourke N, Martin IJ. Laparoscopic versus open ventral hernia repair: A randomised controlled trial. *ANZ J Surg.* 2008;78:903-06. <https://doi.org/10.1111/j.1445-2197.2008.04689.x>.
- [20] O'Connor SC, Carbonell AM. Management of postoperative complications in open ventral hernia repair. *Plast Aesthet Res.* 2019;6:26. <http://dx.doi.org/10.20517/2347-9264.2019.38>.

PARTICULARS OF CONTRIBUTORS:

1. Assistant Professor, Department of Surgical Gastroenterology, Karnataka Institute of Medical Sciences, Hubballi, Karnataka, India.

NAME, ADDRESS, E-MAIL ID OF THE CORRESPONDING AUTHOR:

Mukund Prabhakar Kulkarni,
Ashok Nagar, Hubballi, Karnataka, India.
E-mail: mukundaiims@gmail.com

PLAGIARISM CHECKING METHODS: [Jan H et al.]

- Plagiarism X-checker: Dec 28, 2020
- Manual Googling: Mar 11, 2021
- iThenticate Software: Apr 13, 2021 (9%)

ETYMOLOGY: Author Origin

AUTHOR DECLARATION:

- Financial or Other Competing Interests: None
- Was Ethics Committee Approval obtained for this study? Yes
- Was informed consent obtained from the subjects involved in the study? Yes
- For any images presented appropriate consent has been obtained from the subjects. Yes

Date of Submission: **Dec 22, 2020**

Date of Peer Review: **Feb 06, 2021**

Date of Acceptance: **Apr 06, 2021**

Date of Publishing: **Jul 01, 2021**